

***Piper Sarmentosum* Leaf as a Promising Non-Toxic Antiparasitic Agent against *Trypanosoma Evansi*-Induced Mice**

Mohd Shukri Baba^{1*} and Zainal Abidin Abu Hassan²

¹ Department of Biomedical Science, Kulliyyah of Allied Health Sciences, International Islamic University Malaysia, Jalan Sultan Ahmad Shah, 25200 Kuantan, Pahang, Malaysia.

² Department of Parasitology, Medical Faculty, Universiti Teknologi MARA, 40450 Shah Alam, Selangor, Malaysia

Abstract

Realizing that *Trypanosoma evansi* is now has been potentially trans-infected to human from animals, this study demonstrated how the manipulation of natural plant, *Piper sarmentosum*, promisingly can solve the endemicity of vector-borne zoonotic manifestation of atypical human trypanosomiasis (AHT) and Surra disease in livestock. Groups of male mice were intraperitoneally administered with the parasite at 5.0×10^3 T. *evansi*/mouse and orally given pre- and post-infection treatments with 0.2 mL of 10 mg/mL of *P. sarmentosum*-dH₂O extract per mouse. By using Giemsa stained blood smear, the development of parasite cells, toxicity level of mice blood enzymes, histopathology of selected organs and survival rate of the mice were investigated. The morphological changes of T. *evansi* cells were evidenced and a positive correlation ($p \leq 0.05$, $n = 6$) were recorded between the mice survival time and the ability to inhibit the parasites growth in pre-infection treatment group, PRE14. Besides, PRE14 group was also recorded the longest pre-patent and survival period. The mice blood enzymes were significantly situated in the normal ranged and no abnormalities were found on the selected organs. This study evidenced that *P. sarmentosum* could be manipulated as a potential antiparasitic alternative drug towards trypanosomiasis.

Keywords: *Piper sarmentosum*, *Trypanosoma evansi*, haemoflagellate, giemsa blood smear

Article Info

Received 30th May 2019

Accepted 24th September 2019

Published 2nd December 2019

*Corresponding author: Mohd Shukri Baba; e-mail: mohd_shukri@iium.edu.my

Copyright Malaysian Journal of Microscopy (2019). All rights reserved. ISSN: 1823-7010 eISSN: 2600-7444

Introduction

Surra disease, a vector-borne disease in most of the livestock that caused by the etiological agent haemoflagellate protozoa *Trypanosoma evansi* is still a great concern for some tropical countries where cattle industry is practiced and that drug-resistant become almost unavoidable [1]. A review study was conducted by integrating geographic information system (ArcGIS 9.3) where a total of 67 cases were reported positive *T. evansi* within the period of study (2000-2013), whereby the highest positive *T. evansi* case was observed in Perak (88.05%, 59 cases) [2]. Since its isolation from naturally infected cattle in late 1980's, the maintenance of *T. evansi* in laboratory animals has become established and very useful for the study of trypanosomiasis in general [1]. What is more worrying is this disease is now being considered as zoonosis as it can be spread to human and caused atypical human trypanosomiasis (AHT) [2]. Out of 19 AHT cases documented from 1917 to 2010, five of them were caused by *T. evansi* [3]. This should be resolved since the impact of these diseases will influence the growth of the nation's economy and country's development strategies [4, 5].

Piper sarmentosum leaf or commonly known as 'kaduk' in Malay [6] is one of the crops that usually used as local cuisine especially in Southern and Southeast Asian regions [7]. Clustered in Piperaceae family, this plant possess many phytochemical elements including high antioxidant compound such as Vitamin A and E, carotenoids, xanthophyll, tannins and fairly high amounts with sodium, magnesium and zinc [8,9]. *P. sarmentosum* also exhibited antibacterial activities against *E. coli*, *Burkholderia* spp. and *Haemophilus parasuis* [10] as well as larvicidal activity against mosquitoes due to its phenyl-propanoids component [7]. Beside its anti-inflammatory and anti-atherosclerotic properties [11], previous study also evidenced that the flavonoids of *P. sarmentosum* have a great potential for hepatic injuries remedy [6] and cardiovascular treatment [8, 9].

By far, there are very limited studies documented on the antiparasitic properties of *P. sarmentosum*, particularly against *T. evansi*. Realizing many studies had evidenced that the herbs and plants utilized by the human as their daily alternative medicine to treat many vector borne diseases [7, 12, 13], this study was aim to evaluate the *in-vivo* antiparasitic activities of *P. sarmentosum* aqueous extract against *T. evansi* in mice. Besides, the morphological changes of parasite cells, toxicity of blood enzymes activity and the histopathology assessment on the mice liver and kidney were also investigated in this study.

Materials and Methods

Aqueous extract of Piper sarmentosum

About 2.0 kg *P. sarmentosum* was bought from a market at Jalan Pasar, Kuantan, state of Pahang, Malaysia. This plant was then identified by Dr. Shamsul Khamis, a botanist from Kulliyyah of Pharmacy, IIUM with the voucher number PIIUM-0239-4. The leaf was washed with dH₂O before cut into small pieces and rewashed. The remaining 1.8 kg of cut *P.*

sarmentosum leaf was blended with 2.0 L of sterile dH₂O (sdH₂O) until uniform consistency is achieved before it was allowed to stand overnight at 28 °C and filtered to get concentrated solution of *P. sarmentosum*.

These steps were repeated for three times. The total filtered solution was combined into several containers for freeze drying processes before 280 g of *P. sarmentosum* aqueous extract in powder form were collected as a final product and stored in the refrigerator at 4 °C. To initiate the treatment, this powder was diluted into sdH₂O to achieve its targeted dosage and concentration (0.2 mL of 10 mg/mL of *P. sarmentosum*-dH₂O extract per mouse).

Experimental animal

All animal experiments were conducted following approval by the Institutional Animal Care and Use Committee of IIUM coded IIUM/IACUC-2017(8). The ICR strain male mice with 25-30 g body weight (bw) and 6 – 8 weeks old were used throughout this study. The handling and management of the mice were organized based on the guidelines provided by IACUC-IIUM where every mice group (n = 6 per group) have been placed in stainless steel cages and were put at 28 °C. All of the mice groups were given daily *ad-libitum* treated with grain and cereal-based diets (standard chows) and water at 12-12 hours both with and without light periods.

Preparation of Berenil solution

In this study, commercial anti-trypanosomal drug, Berenil (Hoechst Ag) (Sigma-Aldrich, Malaysia) in powder form has been used. As labeled, each 2.36 g of granulated powdered granules contains 1.05 g of 4, 4'-diamidino diazoaminobenzin diacetamidoasitate. The therapeutic dosage of 3.5 mg/kg bw [14, 15] in each 0.01 mL solution was prepared as instructed and intraperitoneally (i.p) injected into each mice.

Parasite inoculum

T. evansi stock was obtained from Parasitology Laboratory, Faculty of Veterinary Medicine, Universiti Putra Malaysia (UPM). To maintain the parasite, the mice were i.p administered with the parasitized inoculum of 0.1 mL Alsever's solution from the donor mice when the percentage of parasitemia density is reaching 20-30%. To initiate the infection, the parasitized solution was serially diluted with Alsever's solution. Later, every experimental mouse were i.p administered with lethal dose of 0.1 mL blood solution containing 5.0×10^3 *T. evansi* on Day-0 (D0) [16,17].

Treatment pattern and study schemes

Nine groups of mice (6 mice per group) which infected with 5.0×10^3 *T. evansi* were used in this study. The positive control group (POS) was treated with 0.01 mL of berenil that singly i.p administered once the parasitemia density reached 40-50%. The negative control group (NEG) was orally treated with 0.1 mL of 0.9% normal saline (NS) starting from D14 pre-infection and daily continued until the mice died. LTN was the lethal infected group with 5.0×10^3 *T. evansi* without receiving any treatments. The next three groups were preventive regime

groups namely PRE14, PRE7 and PRE3 which were orally treated with 0.2 mL of 10 mg/mL of *P. sarmentosum*-dH₂O extract, respectively starting from day D14, D7 and D3 pre-infection and daily continued until the mice died. The rest three groups were curative regime groups namely CUR3, CUR4 and CUR5 which were orally treated with 0.2 mL of 10 mg/mL of *P. sarmentosum*-dH₂O extract, respectively starting from day D3, D4 and D5 post-infection and daily continued until the mice died. Giemsa's stained blood smears were prepared from each mice on every alternate day, starting from D3 post-infection until the mice were died.

Experiment parameters

General microscopy observation and parasitemia measurement

Thorough observation on the parasite's morphology and survival were carried out under computerized light microscope (Zeiss Primo Star, New York Microscope Co., New York, USA and Dell, Dell Global Business Sdn. Bhd., Selangor, Malaysia). Using giemsa's stained blood smears, parasitemias density were calculated on D7 post-infection [14, 16]. The pre-patent period and survival rate of each group of mice were also recorded.

Biochemical toxicity and organ histology assessment

For biochemical toxicity test, another mice group with similar characteristics during antiparasitic screening were also applied towards the blood samples of the mice treated with 0.2 mL of 10 mg/mL of *P. sarmentosum*-dH₂O extract. At the dosage of 0.2 mL 2.0 mg/kg bw of *P. sarmentosum*-dH₂O extract, this phase consist acute toxicity exposure (daily treatment for 7 days) and sub-acute toxicity exposure (daily treatment for 28 days). There were six groups applied in toxicity assessment in this study. Those groups were respectively tagged as AX for acute-treated without infection, AY (acute-treated within 2 hours post-infection), SX (subacute-treated without infection) and SY (subacute-treated within 2 hours post-infection). Another two groups were control groups namely as CX (normal mice without any infection and treatment) and CY (infected mice with lethal dose of 5.0×10^3 *T. evansi*). To run this protocol, all of the mice were sacrificed under diethyl ether anesthesia before 0.8-1.0 mL of the blood was extracted from each mice by cardiac puncture. This was done on D8 and D29 post-exposure for acute and sub-acute toxicity group, respectively. The blood were then analysed for alanine aminotransferase (ALT), alkaline phosphatase (ALP), aspartate aminotransferase (AST) and serum total protein (STP) levels. For indication, all of the results obtained were compared with the normal range value that circulated by The Department of Research Animal Resources, University of Minnesota (MN, USA) for comparison. On the same sacrificed mice, the hematoxylin-and-eosin (H&E) stained slide of the extracted kidney and liver were also prepared [18] before these slides were then observed by using the computerized light microscope as previously mentioned.

Statistical analysis

The Shapiro-Wilk test was used to analyse the significance of the tests. All the results for antiparasitic screening and biochemical toxicity test were expressed as the mean \pm standard error

(SE). All of the mice groups were normally distributed and the significance of the test was statistically declared when P value is equal to or less than 0.05 ($P \leq 0.05$).

Results and Discussion

Pre-patent period

For preventive regime, longer pre-patent period were recorded for all 3 groups ranging from 20.02 ± 4.18 to 42.71 ± 1.50 days (Table 1). There were significant differences ($p < 0.05$, $n = 6$) of achieved pre-patent period in all preventive group mice as compared to the other treatment group where PRE14 has recorded the highest period. This shows that daily pre infection

treatment significantly can affect the duration of the emergence and development of *T. evansi* in the host. For curative regime, all three groups were recorded shorter pre-patent period within 7 to 8 days which may cause the mice to survive at least up to 16 days only. In general, the sooner the treatment of *P. sarmentosum* aqueous extract, the longer the pre-patent period was recorded. Prophylactic treatment of *P. sarmentosum* aqueous extract can delay the pre-patent period as compared to the other treatment regimens and this has given the opportunity for mice to survive longer. There would be many intrinsic factors that influencing the time taken for the parasite to increase its cellular number up to detectable level in the peripheral blood [14]. These factors include the length of time it takes for the parasite to complete the binary fission process and the host's capacity to counter high parasitaemias with protective activities albeit immunity [15, 18]. It is hypothesize that the delayed of pre-patent period recorded for preventive regime groups could be due to an early action of bioactive compounds contained in *P. sarmentosum* which suppressed the parasite cells growth [19,20].

Parasitemia density

PRE14 group was recorded the lowest peak parasitemia density (23.05 ± 3.36 %) among all experimental groups except the POS group (Table 1). This result suggested that preventive regime of daily treatment with 0.2 mL of 10 mg/mL of *P. sarmentosum*-dH₂O extract was more effective in suppressing the early development of parasitemia than daily curative treatment. Three of curative groups showed a similar pattern of parasitemia development where the peak value were recorded between 32 % and 38 %. These percentages were relatively higher which may suggesting that post-infection treatment is not effective to prolong the survival period of the host. The peak parasitemia density value for POS group was dropped dramatically from 39.09 ± 2.02 % to 0 % within 6 hours on D8 post-infections after being administered with 0.01 mL of berenil solution.

Survival time

Statistically, a significant difference ($p < 0.05$, $n = 6$) was evidenced for the survival period for the mice in preventive treatment groups. As comparison to all *P. sarmentosum*-treated groups, it can be summarized that the longer and the earlier the duration of preventive treatment, the longer the survival rate of the host. The mice survival period for preventive groups was within 285 – 104 days where these values were far longer among all experimental groups

received *P. sarmentosum* extract treatment (Table 1). The mice in POS group were succeeded in continuing its survival for more than 12 months after an infection. Hence, it can be concluded that prophylactic or preventative treatment can provide opportunities for the infected hosts to live longer. The survival period for the curative treatment group is not much different as compared to the LTN group which only receives a fatal infection of 5×10^3 *T. evansi*. Thus in parallel with previous studies [12, 14, 15], generally, the curative treatment groups significantly have no antiparasitic effect on the lifespan of the infected host although the treatment is given daily and persistently.

Table 1. Pre-patent period (day), parasitemia density (%) on D7 post-infection and survival time (day) of the mice group treated with 0.2 mL of 10 mg/mL of *P. sarmentosum*-dH₂O extract as compared with all control groups

Regime	Group	Pre-patent period (day)	Parasitemia density (%)	Survival time (day)
Preventive	PRE14	42.71 ± 1.50* [§]	23.05 ± 3.36* [§]	285.15 ± 3.62* [§]
	PRE7	27.64 ± 3.81* [§]	29.26 ± 1.55*	193.66 ± 2.05* [§]
	PRE3	20.02 ± 4.18* [§]	30.97 ± 1.10*	104.79 ± 3.22* [§]
Curative	CUR3	8.82 ± 3.16*	32.78 ± 0.99*	30.09 ± 1.19*
	CUR4	8.06 ± 3.20*	35.08 ± 3.07*	21.11 ± 4.23*
	CUR5	7.63 ± 2.11*	38.13 ± 2.63*	16.29 ± 3.03*
Control	POS	5.63 ± 1.91*	39.09 ± 2.02*	>360
	NEG	6.97 ± 4.44*	41.79 ± 3.11*	10.18 ± 2.47*
	LTN	5.08 ± 2.07*	40.09 ± 0.30*	9.75 ± 3.06*

.Notes: (*) Value in mean ± standard error (SE). (̂) Value with significant different (P≤0.05, n=6). **PRE14**: daily preventive treated group starting from 14 days before infection. **PRE7**: daily preventive treated group starting from 7 days before infection. **PRE3**: daily preventive treated group starting from 3 days before infection. **CUR3**: daily curative treated group starting from 3 days after infection. **CUR4**: daily curative treated group starting from 4 days after infection. **CUR5**: daily curative treated group starting from 5 days after infection. **POS**: positive control treatment with single dose 0.01 mL of berenil on D8 after infections. **NEG**: negative control treatment with daily dose of 0.1 mL of 0.9% normal saline starting from day 14th before infection. **LTN**: lethal infected group which received a fatal infection of 5×10^3 parasites per 0.1 ml Alsever's solution.

Parasite morphological changes

Parasites in the POS group had experienced the most severe and adverse morphological changes due to the action of berenil whereby as early as 5-6 hours after treatment, the number of destructed cells was evidenced which lead to the cell death (Figure 1). The microscopic observation towards *T. evansi* cells for preventive groups particularly PRE14 (which had suppressed the parasitemias) were proved having some significant changes and severe cellular damage. Somehow relatively, PRE14 occur at slower rate as compared to the berenil action whereby morphology changes only begin after the completion of the pre-patent period. During the patent infections stage, there are mixed populations of deteriorated and normal parasites in the blood. The detection of normal and destroyed parasitic cell populations requires further clarification. It may indicate that the effect of *P. sarmentosum* extract on the cell was not total and incomplete [13]. Some cells may not be tolerated or were left undeterred by the action of

bioactive compounds or phytochemicals contained in *P. sarmentosum* and thus provide a chance for the parasites continued their growth which then became predominant in peripheral blood and caused lethal infection to the mice. In other similar studies, Zainal-Abidin and his colleagues proves that a compound called allicin that extracted from *Allium sativum* (garlic) can inhibit the growth of *T.evansi* in trypanosomiasis-induced mice [14]. On top of that, *Eiettaria cardamomum* (cardamom) water extract was also outstandingly can block the development of *T. evansi* infection and lead the infected mice survived for almost 30 days [16].

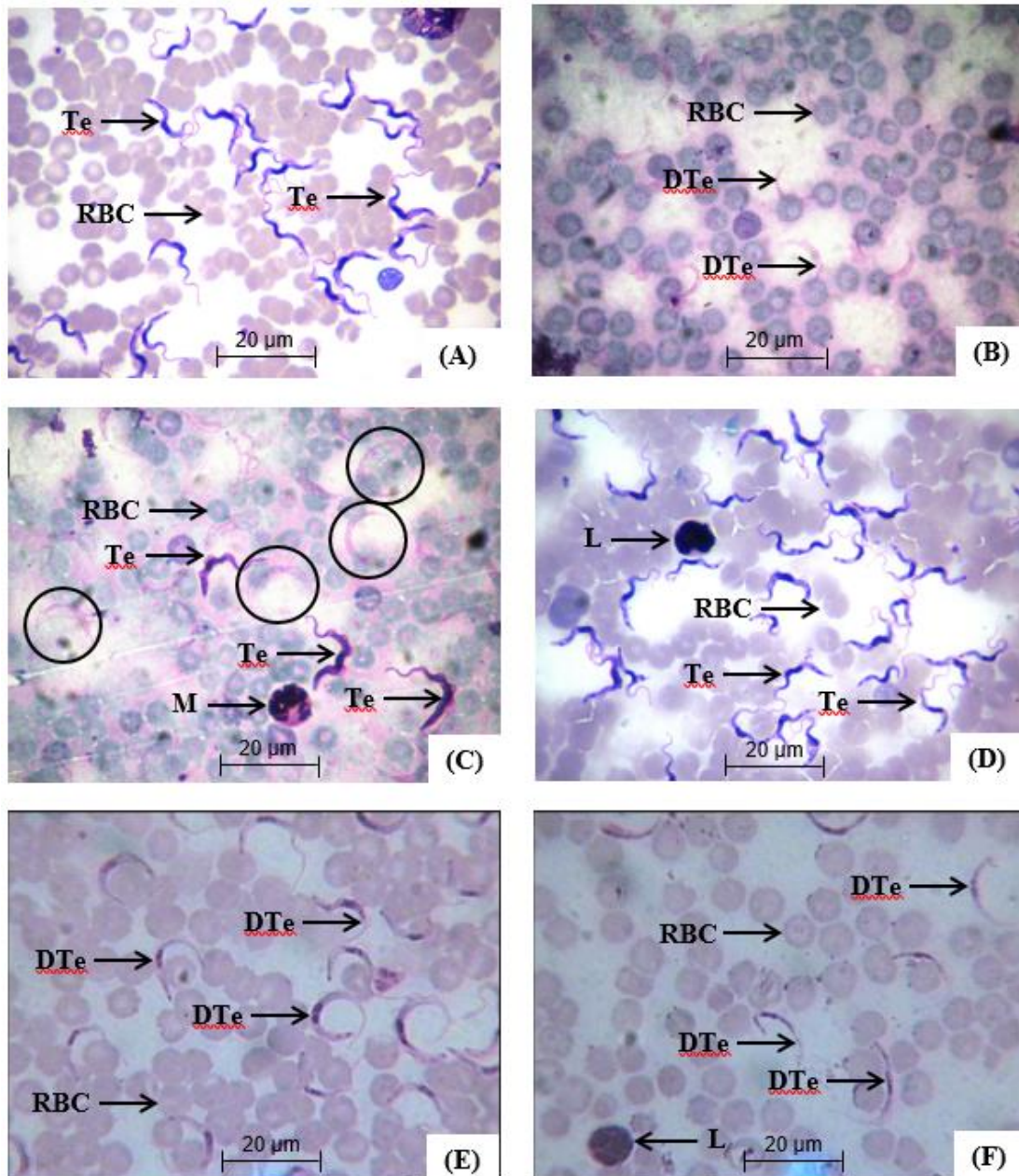


Figure 1. Light micrograph (x100 magnification) shows notable morphology changes of *T. evansi* in preventive mice group (PRE14) treated with 0.2 mL of 10 mg / mL of *P. sarmentosum*-dH₂O extract which was taken on D100 (A) and D250 (B) post-infection. A mixed population of deteriorated *T. evansi* (in the circle) was clearly observed (C) on D280 before the mice dead on

D286. The POS group mice shows drastic morphological changes process of the parasite just within 6 hours as shows in 1st hour (D), 3rd hours (E) and 5th hours (F) post-treatment with single dose 0.01 mL of berenil on D8 after infections before they were totally eliminated on D6. The parasites in POS group became crescent shaped with shrunken cytoplasm and disintegrated undulating membranes before the number of destructed cells was evidenced which lead to the parasite death. Abbreviation: Red blood cell (RBC), lymphocyte (L), monocyte (M), *T. evansi* (Te) and deteriorated *T. evansi* (DTe).

Blood enzyme biochemical tests

With the dosage of 0.2 mL of 10 mg/mL of *P. sarmentosum*-dH₂O extract, the results of the biochemical toxicity test in this study revealed that all enzymes and total protein serum protein (STP) for all tested groups were situated within the normal range (Table 2). The Department of Research Animal Resources, University of Minnesota (MN, USA) [21] documented that ALT, AST, ALP and STP values may change and can be varied and beyond the normal levels depending on the age, weight, sex and type and strain of animal models. In general, almost all of enzymes will be over-secreted in parallel with the maturation process and increasing age of the animals [22, 23]. Thus the normal range of the enzymes was set up basically according to the animal’s age. The increased of ALT (>100 IU/L) and AST (>200 IU/L) levels in ruminant animals infected with *T. evansi* are likely due to tissue breakdown (necrosis) and inflammation in the host, particularly liver, kidney and muscle [24] where all of these factors were not observed in this study. Another possibility of increased levels of ALT and AST enzymes is the lysed trypanosomes at different stages of the infection [25] whereby this factor is not one of parameter for this study. In trypanosomiasis infected host, the elevation in ALP level for >110 IU/L and STP activities (10 g/dL) might be attributed to hepatic toxicosis as well as the parasites secreted their metabolites into blood circulation [26]. This elevation could be also attributed to the cellular damage caused by the trypanosomes lysis or host destruction of trypanosomes [24, 26]. Basically, in any parasitic infected-host, the reduction of ALP, AST, ALT and STP suggested hepatic damage, hypoproteinemia, hypoalbuminemia, anemia and thrombocytopenia [26]. Somehow all of these scenario were not considered in this study.

Table 2. The level of ALT, AST, ALP (IU/L) and STP (g/dL) of the mice group treated with 0.2 mL of 10 mg/mL of *P. sarmentosum*-dH₂O extract as compared with control groups

Regime	Group	ALT (IU/L)	AST (IU/L)	ALP (IU/L)	STP (g/dL)
Acute exposure	AX	52.91 ± 2.09*	155.20 ± 1.71*	63.56 ± 3.02*	7.97 ± 3.02*
	AY	49.77 ± 1.36*	139.49 ± 3.01*	75.80 ± 2.76*	6.20 ± 1.94*
Sub-acute exposure	SX	75.05 ± 2.80*	172.05 ± 2.99*	84.48 ± 0.96*	7.55 ± 2.16*
	SY	60.61 ± 2.94*	122.46 ± 3.22*	90.07 ± 1.42*	8.61 ± 0.99*
Control	CX	45.86 ± 3.11*	160.08 ± 1.16*	89.19 ± 1.72*	6.83 ± 2.44*
	CY	67.90 ± 1.04*	188.64 ± 0.79*	77.07 ± 2.20*	7.05 ± 3.70*
Indicator	NR	40 – 93	92 – 206	54 – 115	5.8 – 9.5

Notes: (*) Value in mean \pm standard error (SE). **AX:** acute exposure for 7 days without infection, **AY:** acute exposure for 7 days started within 2 hours after infection, **SX:** sub-acute exposure for 28 days without infection, **SY:** sub-acute for 28 days started within 2 hours after infection, **CX:** normal control mice without any infection and treatment, **CY:** single lethal-dose of *T. evansi* infected mice. **NR:** normal range data for ICR strain male mice aged 8 weeks old for indicator as circulated by Department of Research Animal Resources, University of Minnesota, MN, USA. Abbreviations: **ALT:** alanine aminotransferase, **AST:** aspartate aminotransferase, **ALP:** alkaline phosphatase, **STP:** serum total protein, **IU/L:** international unit per litre, **g/dL:** gram per decilitre.

Organ histology assessment

Theoretically, any suspicious abnormalities observed on five vital organs; kidney, liver, spleen, brain and lungs during the process of organ isolation, histologically it will be also expected to be observed in H&E staining of these organs [27], where this phenomenon are also occurred in this study. Neither acute treatment (7 days) or subacute treatment (28 days) regimens, nor the control treatment group, there were no active kupffer cells, cytoplasmic vacuolation and absorbable sinusoidal dilatation was observed in the liver. All these characteristics, if presence, were basically as the indicator of the abnormalities and toxicity of liver parenchymal cells [28]. As evidenced in Figure 2, there was no hepatic injury was observed in any treatment groups. Hepatic injuries are interpreted as congestive nuclear changes, minor changes in vascular inflammation and the emergence of necrosis and cytoplasmic condensation [29]. Since this study uses *T. evansi* as an etiological agent, histologically, the toxicity effects on the liver and kidneys are most relevant to be investigated in terms of physical injuries, cellular abnormalities and morphological changes of the targeted organs [3, 30]. Unlike for *T. vivax*, *T. lewisi* and *T. congolense*, it will be the best to observe and justify the toxicity effects on the host's brain, spleen and lungs particularly in any atypical human trypanosomiasis (AHT) researches [31,32,33,34]. *T. evansi* is highly pathogenic in laboratory animals such as mice and rat [35]. Microscopic examination showed significant histopathological changes in different organs especially liver and kidney and in most examined tissues the parasite was detected in high numbers [35]. Evolutionarily, since the existence of *T. evansi* was derived from *T. brucei* [16], it can be hypothesized that this parasite is highly potential can affect both human and livestock and how the prevalence of AHT nowadays is well documented. In trypanosomiasis research, it is very important to understand the progress and development of the disease by taking into account the histopathology effect on the host's vital organs. As it can act as both intra- and extra-cellular flagellate protozoa, the phenomenon of pseudolobule formation, necrosis and hemorrhage within the sinusoids and fatty degeneration of hepatic cells are potentially can be occurred in the liver [G, I, J] and infiltration of lymphocytes, hemorrhage in the interlobular space and glomerulitis as the irreversible and destructive changes are easily can be observed in the kidney [35, 36]

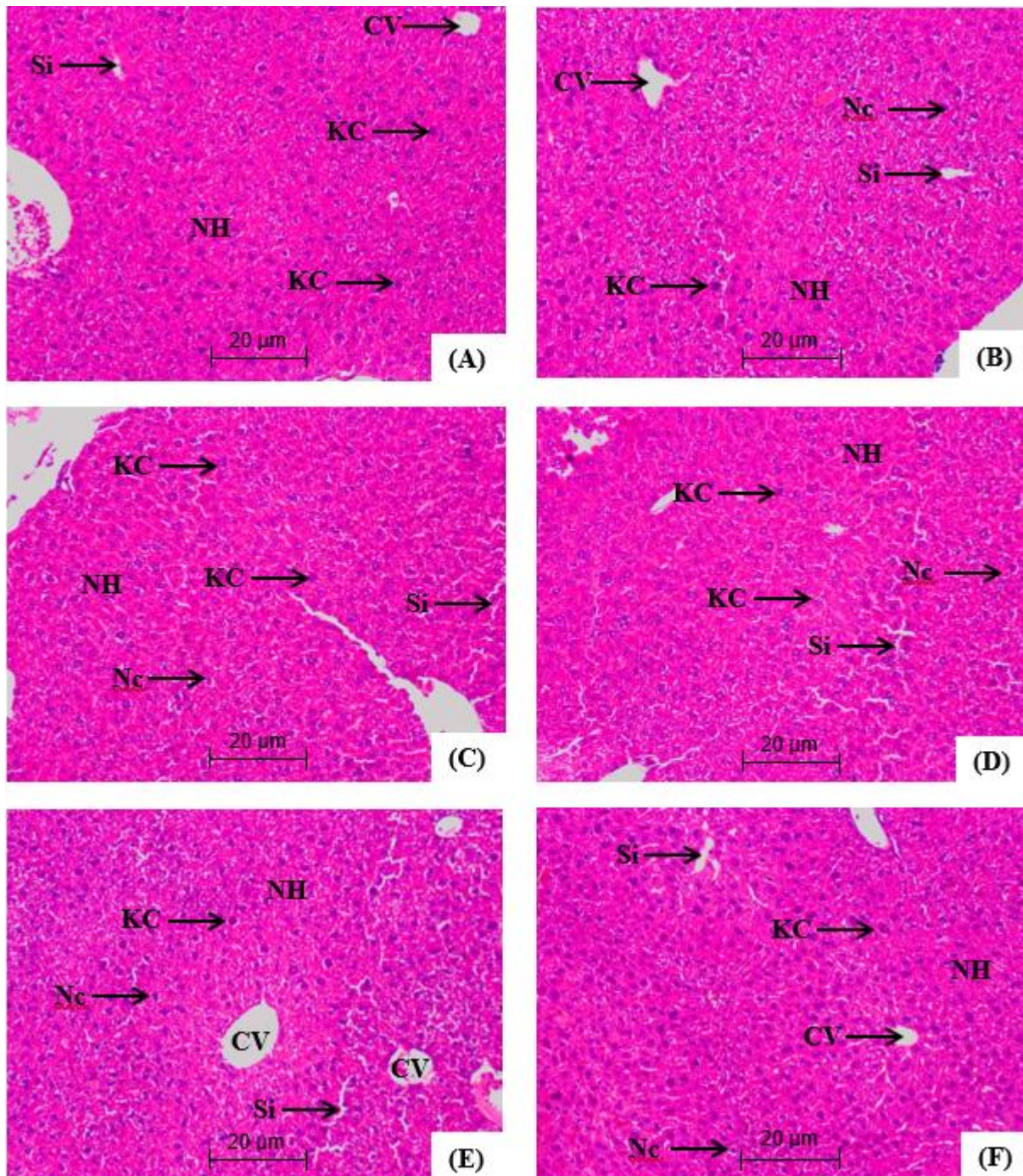


Figure 2. The microscopic H&E histology slides view (100× magnification) of the liver of selected preventive treated mice from group AX (A), AY (B), SX (C) and SY (D) as compared with normal control mice from group CX(E) and group CY (F). Hepatic structure was in normal condition and in general shows no abnormality characteristics as well as no pathological and morphological injuries. Abbreviation: normal hepatocytes (NH), central vein (CV), normal nuclei (Nc), sinusoid (Si) and Kupfer cell (KC).

There was no indication of cellular and granular cast formation that can be observed on the kidney tissue for all treatment groups (Figure 3). The glomerular and tubule structure of this organ were shows no morphological abnormalities. It can also be noted that there was no glomerular atrophy and tubule necrosis, as well as no vascular shrinkage can be observed in the kidney tubular in the cortical zone, which was directly indicated the degenerative phenomenon [37,38].

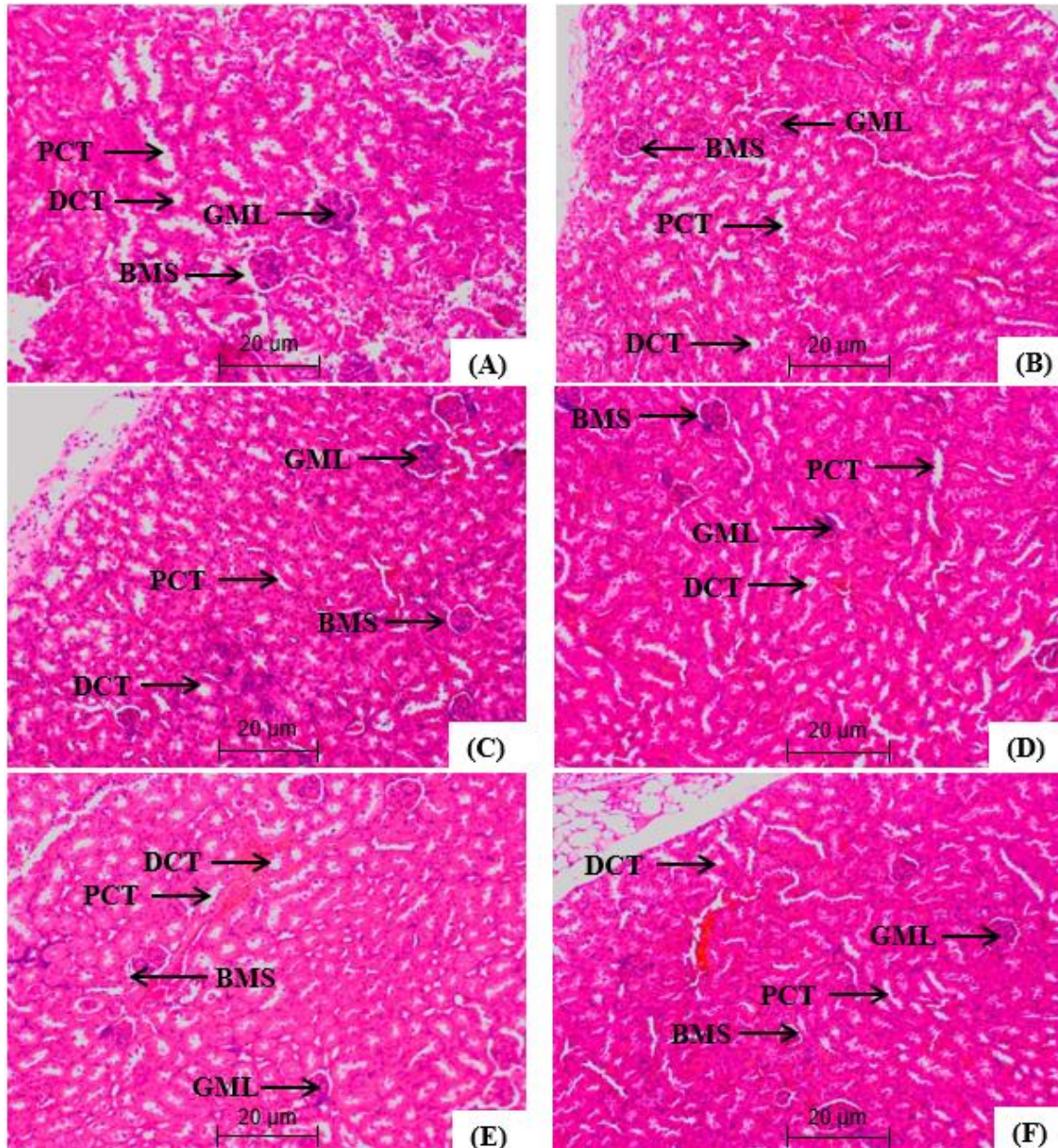


Figure 3: The microscopic H&E histology slides view (100× magnification) of the kidney of selected preventive treated mice from group AX (A), AY (B), SX (C) and SY (D) as compared with normal control mice from group CX (E) and group CY (F). Renal structure was normal and basically shows no pathological changes and morphological abnormalities. Abbreviation: normal

glomeruli (GML), Bowman's space (BMS), proximal convoluted tubule (PCT) and distal convoluted tubule (DCT).

Conclusion

P. sarmentosum aqueous extract may contain some bioactive compounds with anti-trypanosomal properties that need to be studied in depth. The two treatment regimens proposed in this study are in accordance with the real prophylactic and curative treatments for treating surra disease in livestock and AHT patients. Basically, the earlier continuous prophylactic administration of *P. sarmentosum* to the host, then the more promising and convincing results would be obtained in inhibiting and suppress parasitemia levels and parasite growth. Therefore, it is advisable that *P. sarmentosum* should be consumed and taken by humans as healthy vegetable at all times. Besides, none of the liver and kidney tissues showing any disorders as well as no morphological differences between control and treatment groups, whether this group has been given acute or subacute regimens. In parallel, there is no physical or swelling injury, morphological abnormalities or discoloration on these liver and kidney tissues that have been observed during the isolation process from the sacrificed mice. Hopefully this study will be a stepping stone towards the basic exploration of *P. sarmentosum* as an optional plant for the treatment of surra and AHT disease.

Acknowledgement

The authors greatly acknowledge to the Kulliyyah of Allied Health Sciences (KAHS) International Islamic University Malaysia (IIUM) for providing facilities and financial supports.

Author Contributions

All authors contributed towards data analysis, drafting and critically revising the paper and agree to be accountable for all aspects of the work.

Disclosure of Conflict of Interest

The authors have no disclosures to declare.

Compliance with Ethical Standards

The work is compliant with ethical standards.

References

- [1] Da Silva AS, Kroeker Duck MR, Da Rosa FV, Otto MA, Nunes JTS, Tonin AA, Jaques JA, Paim FC, Frescura Duarte MMM, Monteiro SG. Trypanocidal activity of human plasma on *Trypanosoma evansi* in mice. *Re Bras Parasito Vet* 2012; 21(1):1-5.
- [2] Masrin A. Chandrawathani P. Premaalatha B. Erwanas AL. Sharil AMZ. Fakhrulisham R. Matavi M. Review on the Distribution of *Trypanosoma evansi* Infection in Malaysia.

- [3] Philippe T, Philippe Bu Ge´rard C, Mary IG, Jean J, Prashant J, Prayag J, Zhao-Ron L, Raffaele M, Etienne P, Pere PS, Marta-Maria GT, Louis T, Philippe V, Marc D. Atypical human infections by animal Trypanosomes. *PLOS Neglected Tropical Disease* 2013; 7(9):e2256.
- [4] Singh D, Kumar S, Singh B, Bardhan D. Economic losses due to important diseases of bovines in central India. *Veterinary World* 2014; 7(8):579-585.
- [5] Lazuardi M. In-vitro drug sensitivity of *Trypanosoma evansi* Bengkalan isolates. *Folia Medica Indonesiana* 2018; 41(1):43-48.
- [6] Azlina M, Qodriya H, Hamizah A, Kamisah Y. Effects of methanolic extract of *Piper sarmentosum* on paracetamol-induced hepatic oxidative injury in rats. *Sains Malaysiana* 2014; 43(3):415-421.
- [7] Hematpoor A, Liew SY, Chong WL, Azirun MS, Lee, VS, Awang K. Inhibition and Larvicidal Activity of Phenylpropanoids from *Piper sarmentosum* on Acetylcholinesterase against Mosquito Vectors and Their Binding mode of Interaction. *PLOS ONE* 2016;11(5):e155265.
- [8] Hussain K, Hashmi FK, Latif A, Ismail Z, Sadikun A. A review of the literature and latest advances in research of *Piper sarmentosum*. *Pharmaceutical Biology* 2012; 50(8):1045-1052.
- [9] Rahman SFSA, Sijam K. Omar D. *Piper sarmentosum* Roxb: A Mini Review of Ethnobotany, Phytochemistry and Pharmacology. *J Anal Pharm Res* 2016; 2(5):00031.
- [10] Lee JH, Cho S, Paik HD, Choi CW, Nam KT, Hwang SG, Kim SK. Investigation on antibacterial and antioxidant activities, phenolic and flavonoid contents of some thai edible plants as an alternative for antibiotics. *Asian-Australasian Journal of Animal Sciences* 2014;27(10): 1461-1468.
- [11] Zakaria Z. Patahuddin H. In vivo anti-nociceptive and anti-inflammatory activities of the aqueous extract of the leaves of *Piper sarmentosum*. *Journal Ethnopharmacol* 2010;128(1):42-48.
- [12] Abdulelah HA. Zainal-Abidin BAH. In vivo antimalarial test of *Nigeila sativa* (black seed). *American Journal of Pharmacology and Toxicology* 2007; 2(1):46-50.
- [13] Baba MS, Zainal-Abidin BAH, Latip J, Herron PR, Pethick F, Hunter IS, Zin NM. Antimalarial activity of the endophytic actinobacterium *Streptomyces* SUK 10. *Journal of Microbiology* 2015; 53(12):847-855.
- [14] Zainal-Abidin BAH, Baba MS. Allicin-Induced Cellular Destruction of Haemoflagellate Protozoa, *Trypanosoma evansi* In Mice. *Sains Malaysiana* 2011; 40(6):595-599.
- [15] Howes F, Da Silva AS, Athayde CL, Costa MM, Corrêa MMB, Traveres KCS, Miletti LC, Anjos Lopes ST, Amaral AS, Schmidt C. A New Therapeutic Protocol for Dogs Infected with *Trypanosoma evansi*. *Acta Scientiae Veterinariae* 2011; 39(3):988-991.
- [16] Baba MS, Zainal-Abidin BAH. The effects of nerolidol, allicin and berenil on the morphology of *Trypanosoma evansi* in mice: A comparative study using light and electron microscope approaches. *Malay. Applied. Biol* 2011; 40(1):25-32.
- [17] Talakal TS, Dwivedi SK, Sharma SR. In vitro and in vivo antitrypanosoma potential of nycanthes arbor-tristis leaves. *Pharmaceutical Biology* 2000;38(1):326-329.
- [18] Zin NM, Baba MS, Zainal-Abidin BAH, Latip J, Mazlan NW, Edrada-Ebel RA. Gancidin W, a potential low toxicity antimalarial agent isolated from an endophytic *Streptomyces* SUK10. *Drug Design, Development and Therapy* 2017; 11(1):351-363.

- [19] Romão PRT, Tovar J, Fonseca SG, Moraes RH, Cruz AK, Hothersall JS, Noronha-Dutra AA, Ferreira SH, Cunha FQ. Glutathione and the redox control system trypanothione/trypanothione reductase are involved in the protection of *Leishmania* spp. against nitrosothiol-induced cytotoxicity. *Brazilian Journal of Medical and Biological Research* 2016; 39(3):355-363.
- [20] Sanusi NA, Umar RA, Zahary MN, Rohin MAK, Pauzi MR, Ismail S. Chemical Compositions and Antimicrobial Properties of Piper Sarmentosum- A Review. *IOSR Journal of Dental and Medical Sciences* 2017; 16(8):62-65.
- [21] Guidelines for Research Animal Resources, Department of Research Animal Resources, University of Minnesota (MN), USA.
<http://www.ahc.umn.edu/rar/refvalues.html>.
- [22] Adegunloye AP, Tijjani H, Adeuga GA. Hepatic and Renal Effect of Short Term Co-Administration of Artesunate-Amodiaquine and Metformin in Albino Rats. *Asian Journal of Biochemical and Pharmaceutical Research* 2015; 3(5):32-39.
- [23] Obinnal VC, Kagbo HD, Agu, GO. Hepatic and renal biochemical profile of albino rats exposed to chloroform and methanol leaf extracts of *Portulaca oleracea* Linn. *European Journal of Medicinal Plant* 2018; 25(3):1-14.
- [24] Sivajothi S. Rayulu VC. Reddy BS. Haematological and biochemical changes in experimental Trypanosoma evansi infection in rabbits. *Journal of Parasite Discovery* 2015; 39(2):216-220
- [25] Reddy BS. Kumari KN. Sivajothi S. Rayulu VC. Haemato-biochemical and thyroxin status in Trypanosoma evansi infected dogs. *Journal of Parasite Discovery* 2016; 40(2):491-495
- [26] Faten A. Abo-Aziza M. Heba MA. Nassar SA. Haematological and biochemical alterations in sub-clinically affected dromedary camels with Trypanosoma evansi During Breeding Season in Egypt. *Journal of Chemical and Pharmaceutical Sciences* 2017; 10(3):1326-1334
- [27] Thanaporn R, Phantip C, Sebastian KK. Effect of malaria infection and dexamethasone on spleen morphology and histology. *Southeast Asian Journal of Tropical Medicine and Public Health* 2010; 41(1):1290-1296.
- [28] Arsad SS, Esa NM, Hamzah H. Histopathologic changes in liver and kidney tissues from male sprague dawley rats treated with *Rhaphidophora decursiva* (Roxb.) schott extract. *Journal of Cytology and Histology* 2014; 4(1):10-18.
- [29] Lim AY, Segarra I, Chakravarthi S, Akram S, Judson JP. Histopathology and biochemistry analysis of the interaction between sunitinib and paracetamol in mice. *BMC Pharmacology* 2010; 10(14):14-30.
- [30] Biswas D. Choudhury A. Misra KK. Histopathology of trypanosoma (trypanozoon) evansi infection in bandicoot rat visceral organs. *Experimental Parasitology* 2001; 99(3):148-159
- [31] Gardnier PR. Asoku RKG. Whitelaw DD. Murray M. Haemorrhagic lesions resulting from Trypanosoma vivax infection in ayrshire cattle. *Veterinary Parasitology* 1989; 31(4):187-197
- [32] Oliveira LRC. Picka MCM. Nicolete VC. Calvi SA. Marcondes-Machado J. Organ tropism during the acute and chronic phases of Trypanosoma cruzi infection in BALB/C mice. *The Journal of Venomous Animals and Toxins including Tropical Diseases* 2012; 18(1):34-43

- [33] Parashar R. Singla LD. Kaur P. Is atypical human trypanosomosis an emerging threat to human society? : A debatable one health issue to public health experts and parasitologists. *International Journal of Veterinary Science and Research* 2016; 2(1):036-041
- [34] Losos GJ. Ikede BO. Review of pathology of diseases in domestic and laboratory animals caused by Trypanosoma congolense, T. vivax, T. brucei, T. rhodesiense and T. gambiense. *Veterinary Pathology* 1972; 9(1):1-79
- [35] Mohammed AG. Manal EM. Amara FA. Bahaa EDW. Noha EK. Amany F. Atia I. The histopathological effects of Trypanosoma evansi on experimentally infected mice. *Menoufia Medical Journal* 2016; 29(4):868-873
- [36] Seiler RJ. Omar S. Jackson ARB. Meningoencephalitis in naturally occurring Trypanosoma evansi infection (Surra) of horses. *Veterinary Pathology* 1981; 18(3):120-130.
- [37] Finn WF. Portr GA. Urinary biomarkers and nephrotoxicity. *Mineral and Electrolyte Metabolism* 2008; 20(1):92-130.
- [38] Hejazi S, Vaezi Astamal R, Taghizadeh E. Study of kidney histologic changes at cisplatin-treated mice. *International Journal of Biology, Pharmacy and Bioscience* 2014; 3(11):2362-2371.